


2022/2023 RN HESI EXIT EXAM - Version 1 (V1) All 160 Qs &As Included - Guaranteed Pass
A+!!! (All Brand New Q & A Pics Included)



2022/2023 RN HESI

EXIT EXAM

Version 1 (V1) – All 160 Questions & Answers!!

(Actual Screenshots from an Exam taken in April 2022 A+)

(All Included!!)

(I received an 1178 score)

1 of 160

The nurse is completing the admission assessment of a 3-year-old who is admitted with bacterial meningitis and hydrocephalus. Which assessment finding is evidence that the child is experiencing increased intracranial pressure (ICP)?

- ☐ A Tachycardia and tachypnea.
- ☒ B Sluggish and unequal pupillary responses.
- ☐ C Increased head circumference and bulging fontanel.
- ☐ D Blood pressure fluctuations and syncope.

2 of 160

A client with acute pancreatitis is admitted with severe, piercing abdominal pain and an elevated serum amylase. Which additional information is the client **most** likely to report to the nurse?

- ☒ A Abdominal pain decreases when lying supine.
- ☐ B Pain lasts an hour and leaves the abdomen tender.
- ☐ C Right upper quadrant pain refers to right scapula.
- ☐ D Drinks alcohol until intoxicated at least twice weekly.

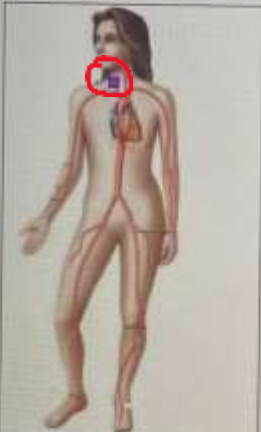3 of 160

A child newly diagnosed with sickle cell anemia (SCA) is being discharged from the hospital. Which information is **most** important for the nurse to provide the parents prior to discharge?

- ☒ A Instructions about how much fluid the child should drink daily.
- ☐ B Signs of addiction to opioid pain medications.
- ☐ C Information about non-pharmaceutical pain relief measures.
- ☐ D Referral for social services for the child and family.

4 of 160

To auscultate for a carotid bruit, the nurse places the stethoscope at what location (Select the correct location on the image. To change, click on a new location.)



#4: I placed the Red dot on the base of the neck on the right side.

5 of 160

After receiving report on an inpatient acute care unit, which client should the nurse assess **first**?

- ☐ A The client with an obstruction of the large intestine who is experiencing abdominal distention.
- ☐ B The client who had surgery yesterday and is experiencing a paralytic ileus with absent bowel sounds.
- ☐ C The client with a small bowel obstruction who has a nasogastric tube that is draining greenish fluid.
- ☒ D The client with a bowel obstruction due to a volvulus who is experiencing abdominal rigidity.

6 of 160

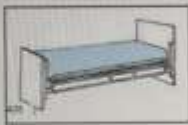A teenager presents to the emergency department with palpitations after vaping at a party. The client is anxious, fearful, and hyperventilating. The nurse anticipates the client developing which acid base imbalance?

- ☐ A Respiratory acidosis.
- ☐ B Metabolic alkalosis.
- ☐ C Metabolic acidosis.
- ☒ D Respiratory alkalosis.

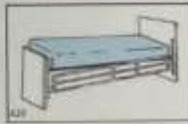7 of 160

A client with dyspnea is being admitted to the medical unit. To best prepare for the client's arrival, the nurse should ensure that the client's bed is in which position?

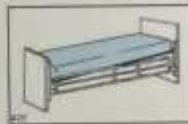☐ A



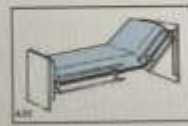☐ B



☐ C



☒ D



Submit and Continue

8 of 160

The nurse is taking the blood pressure measurement of a client with Parkinson's disease. Which information in the client's admission assessment is relevant to the nurse's plan for taking the blood pressure reading? (Select all that apply.)

☒ A Frequent syncope.

☐ B Occasional nocturia.

☒ C Flat affect.

☒ D Blurred vision.

☐ E Frequent drooling.

9 of 160

While caring for a client's postoperative dressing, the nurse observes purulent drainage at the wound. Before reporting this finding to the healthcare provider, the nurse should review which of the client's laboratory values?

☐ A Serum albumin.

☒ B Culture for sensitive organisms.

☐ C Serum blood glucose (BG) level.

☐ D Creatinine level.

10 of 160

A preschool-aged boy is admitted to the pediatric unit following successful resuscitation from a near-drowning incident. While providing care to the child, the nurse begins talking with his preadolescent brother who rescued the child from the swimming pool and initiated resuscitation. The nurse notices the older boy becomes withdrawn when asked about what happened. Which action should the nurse take?

- ☐ A Develop a water safety teaching plan for the family.
- ☒ B Ask the older brother how he felt during the incident.
- ☐ C Tell the older brother that he seems depressed.
- ☐ D Commend the older brother for his heroic actions.

11 of 160

A male client with cirrhosis has jaundice and pruritus. He tells the nurse that he has been soaking in hot baths at night with no relief of his discomfort. Which action should the nurse take?

- ☒ A Encourage the client to use cooler water and apply calamine lotion after soaking.
- ☐ B Obtain a PRN prescription for an analgesic that the client can use for symptom relief.
- ☐ C Suggest that the client take brief showers and apply oil-based lotion after showering.
- ☐ D Explain that the symptoms are caused by liver damage and cannot be relieved.

12 of 160

An older client with a long history of coronary artery disease (CAD), hypertension (HTN), and heart failure (HF) arrives in the Emergency Department (ED) in respiratory distress. The healthcare provider prescribes furosemide IV. Which therapeutic response to furosemide should the nurse expect in the client with acute HF?

- ☐ A Increased cardiac contractility.
- ☒ B Reduced preload.
- ☐ C Relaxed vascular tone.
- ☐ D Decreased afterload.