

Full Test Bank

Anatomy of Orofacial Structures 8th Brand Test Bank

Test Bank [Directly From The publisher](#), 100% Verified Answers.

COVERS ALL CHAPTERS.

[Download Immediately](#) After the Order.

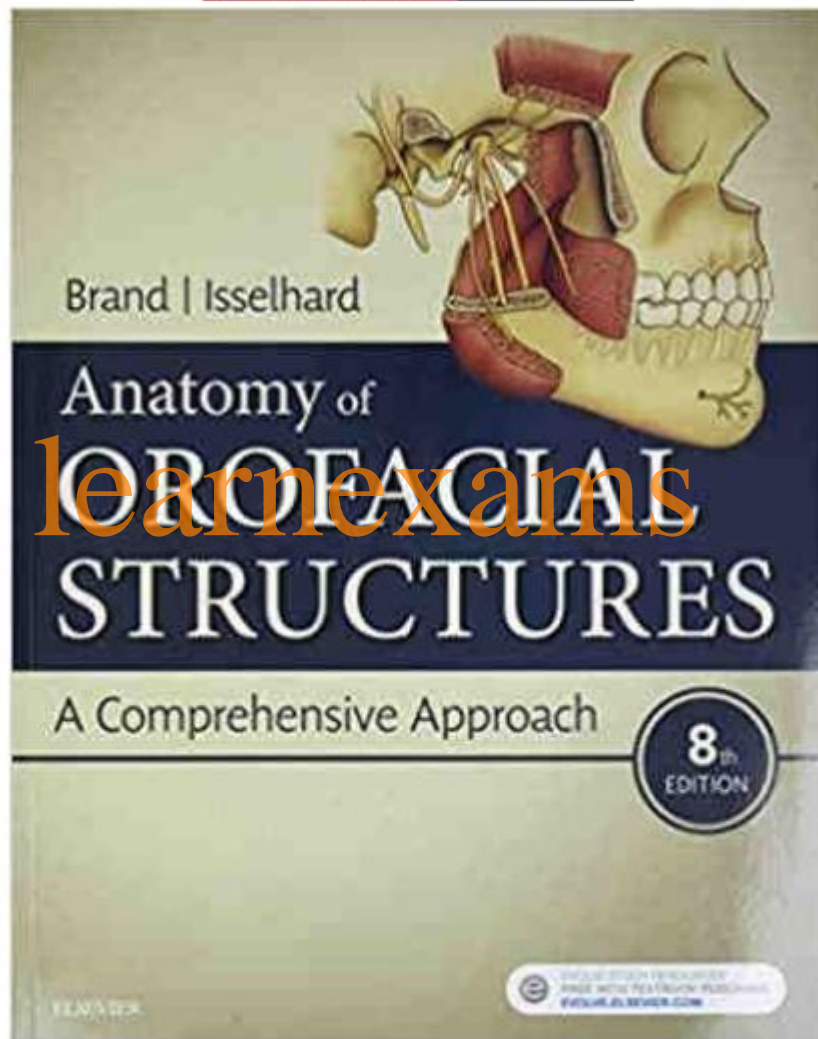


Table of Contents

UNIT I: INTRODUCTION

1. Oral Cavity

UNIT II: DENTAL ANATOMY

2. The Tooth Functions

3. Fundamental and Preventative Curvatures

4. Dentition

5. Development, Form, and Eruption

6. Occlusion

7. Dental Anomalies

8. Supporting Structures

9. Clinical Considerations

10. Tooth Identification

11. Root Morphology

12. Incisors

13. Canines

14. Premolars

15. Molars

16. Deciduous Dentition

UNIT III: ORAL HISTOLOGY AND EMBRYOLOGY

17. Basic Tissues

18. Development of Orofacial Complex

19. Dental Lamina and Enamel Organ

20. Enamel, Dentin, and Pulp

21. Root Formation and Attachment Apparatus

22. Eruption and Shedding of Teeth

23. Oral Mucous Membrane

24. The Tongue

25. Histology of the Salivary Glands

UNIT IV: HEAD AND NECK ANATOMY

26. Osteology of the Skull

27. Nose, Nasal Cavity, and Paranasal Sinuses

28. Muscles of Mastication, Hyoid Muscles, and Sternocleidomastoid and Trapezius Muscles

29. Temporomandibular Joint

30. Muscles of Facial Expression

31. Soft Palate and Pharynx

32. Arterial Supply and Venous Drainage

33. Salivary Glands

34. Nervous System

35. Lymphatics and Spread of Dental Infection

36. Anatomical Considerations in Local Anesthesia Administration

MULTIPLE CHOICE

1. A diastema is a space between two teeth in the same arch. When this occurs between the maxillary central incisors, it is often the result of a pronounced labial frenum.
 - a. Both statements are true.
 - b. The first statement is true; the second statement is false.
 - c. The first statement is false; the second statement is true.
 - d. Both statements are false.

ANS: A

A space, or lack of contact area, between any two teeth in the same arch is called a diastema. When a diastema occurs between the maxillary central incisors, it is often the result of a pronounced labial frenum extending to the crest of the alveolar ridge and possibly over the ridge. This band of firm connective tissue causes the erupting incisors to be pushed aside resulting in a diastema, or space. Correction of a diastema usually involves surgical removal, or cutting, of the frenal tissue between teeth.

REF: p. 3

OBJ: To describe the boundaries and sub-boundaries of the oral cavity and the structures in each area

NAT: CDA: GC I.A.6. Identify basic oral anatomy and physiology, including but not limited to: oral cavity. TOP: BLOOM: Remembering

2. Torus palatinus is seen on the
 - a. soft palate
 - b. hard palate
 - c. alveolar ridge
 - d. oral pharynx

ANS: B

Torus palatinus is excess bone growth and occurs in the midline of the hard palate. It may grow to varying sizes and is generally only a problem when the construction of a maxillary denture is necessary. In health, such bony protuberances, or excess bone growths, do not occur on the soft palate, alveolar ridge, or oral pharynx.

REF: p. 5

OBJ: To define the terms vestibule, oral cavity proper, mucobuccal fold, frenum, alveolar mucosa, gingiva, exostoses, torus palatinus, and torus mandibularis

NAT: CDA: GC I.A.2. Identify basic oral anatomy and physiology, including but not limited to: bones. TOP: BLOOM: Remembering

3. Contraction of which muscle raises the tongue upward?
 - a. Mylohyoid
 - b. Palatopharyngeal
 - c. Palatoglossal
 - d. Levator glossal

ANS: A

Contraction of the mylohyoid muscle raises the tongue. The palatopharyngeal muscle and the palatoglossal muscle form the posterolateral borders of the oral cavity. There is not a muscle by the name of levator glossal.

REF: p. 7

OBJ: To define the landmarks in the floor of the mouth and the hard and soft palate and the structures that form them

NAT: CDA: GC I.A.4. Identify basic oral anatomy and physiology, including but not limited to: muscles. TOP: BLOOM: Remembering

4. The oral vestibule is partially bordered by the lips and cheeks. The oral cavity proper extends posteriorly to the soft palate.
- Both statements are true.
 - The first statement is true; the second statement is false.
 - The first statement is false; the second statement is true.
 - Both statements are false.

ANS: B

The oral vestibule is the space or potential space that exists between the lips or cheeks and teeth. In an edentulous person, the vestibule would extend between the lips or cheeks and the alveolar ridges. The oral cavity proper is surrounded by teeth or alveolar ridges and extends all the way back to the palatine tonsils. This includes the region from the floor of the mouth upward to the hard and soft palates.

REF: p. 2

OBJ: To describe the boundaries and sub-boundaries of the oral cavity and the structures in each area

NAT: CDA: GC I.A.6. Identify basic oral anatomy and physiology, including but not limited to: oral cavity. TOP: BLOOM: Remembering

5. Each of the following is true of the uvula EXCEPT one. Which one is the EXCEPTION?
- It is located at the most posterior portion of the hard palate.
 - It is located at the midline.
 - It is a downwardly projecting muscle.
 - It is necessary for swallowing.

ANS: D

The uvula is a downwardly projecting muscular tissue located at the midline of the most posterior portion of the hard palate. It is NOT necessary for swallowing.

REF: p. 6

OBJ: To define the landmarks in the floor of the mouth and the hard and soft palate and the structures that form them

NAT: CDA: GC I.A.6. Identify basic oral anatomy and physiology, including but not limited to: oral cavity. TOP: BLOOM: Remembering

6. The circumvallate papillae are located on the hard palate, buccal mucosa, and floor of the mouth. The papillae found on the tongue are the filiform, fungiform, vallate, foliate, and incisive.
- Both statements are true.
 - The first statement is true; the second statement is false.
 - The first statement is false; the second statement is true.