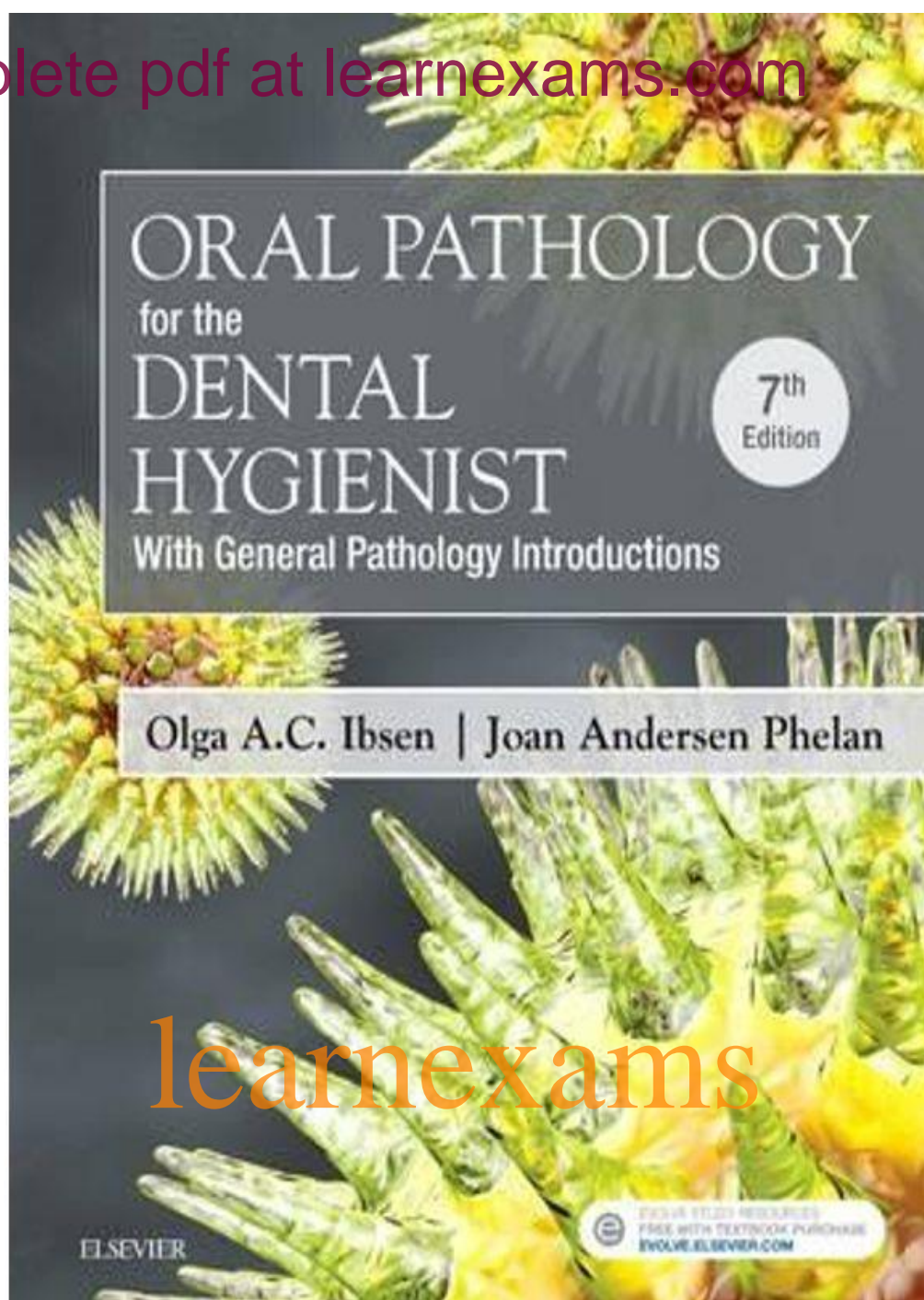


get complete pdf at learnexams.com



learnexams

LEARNEXAMS.COM

Table of Contents

Introduction to Preliminary Diagnosis of Oral Lesions

Inflammation and Repair

Immunity

Infectious Diseases

Developmental Disorders

Genetics

Neoplasia

Nonneoplastic Disease of Bone

Oral Manifestations of Systemic Diseases

learnexams

Chapter 01: Introduction to Preliminary Diagnosis of Oral Lesions
Ibsen: Oral Pathology for the Dental Hygienist, 7th Edition

MULTIPLE CHOICE

1. Which descriptive term is described as a segment that is part of the whole?
 - a. Bulla
 - b. Vesicle
 - c. Lobule
 - d. Pustule

ANS: C

A lobule is described as a segment or lobe that is part of a whole. A bulla is a large, elevated lesion that contains serous fluid and may look like a blister. A vesicle is a small, elevated lesion that contains serous fluid. Pustules are circumscribed elevations containing pus.

REF: Vocabulary, Clinical of Soft Tissue Lesions, page 1 OBJ: 1

2. A lesion with a sessile base is described as
 - a. an ulcer.
 - b. stemlike.
 - c. pedunculated.
 - d. flat and broad.

ANS: D

Sessile describes the base of a lesion that is flat and broad. An ulcer is a break in the surface epithelium. A stemlike lesion is referred to as *pedunculated*. A pedunculated lesion is stemlike or stalk-based (similar to a mushroom).

REF: Vocabulary, Clinical Appearance of Soft Tissue Lesions, page 1
OBJ: 1

3. Which condition is *not* diagnosed through clinical appearance?
 - a. Mandibular tori
 - b. Fordyce granules
 - c. Black hairy tongue
 - d. Compound odontoma

ANS: D

The compound odontoma is initially identified radiographically as a radiopaque area in which tooth structure can be identified. No clinical component exists. Mandibular tori are identified clinically as areas of exostosis on the lingual aspects of mandibular premolars. Fordyce granules are yellow clusters of ectopic sebaceous glands diagnosed through clinical appearance. Black hairy tongue is diagnosed clinically. The filiform papillae on the dorsal tongue elongate and become brown or black. Causes include tobacco, alcohol, hydrogen peroxide, chemical rinses, antibiotics, and antacids.

REF: Radiographic Diagnosis, page 9 OBJ: 3

4. Another name for geographic tongue is

WWW.NURSYLAB.COM

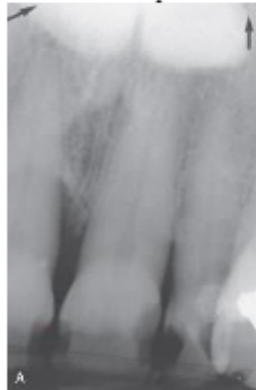- a. median rhomboid glossitis.
- b. benign migratory glossitis.
- c. fissured tongue.
- d. black hairy tongue.

ANS: B

Benign migratory glossitis is another name for geographic tongue. Research suggests that median rhomboid glossitis is associated with a chronic fungal infection from *Candida albicans*. Sometimes the condition resolves with antifungal therapy. Fissured tongue is seen in 5% of the population. It is a variant of normal. Genetic factors are typically associated with the condition. Black hairy tongue is caused by a reaction to chemicals, tobacco, hydrogen peroxide, or antacids. The filiform papillae on the dorsal tongue become elongated and are dark brown to black.

REF: Geographic Tongue, page 24 OBJ: 7

5. This bony hard structure in the midline of the hard palate is genetic in origin and inherited in an autosomal dominant manner. The diagnosis is made through clinical appearance. Which condition is suspected?



GRADESMORE.COM

- a. Palatal cyst
- b. Torus palatinus
- c. Mixed tumor
- d. Ranula

ANS: B

A torus palatinus is developmental and bony hard and is found on the midline of the palate. Diagnosis is made on the basis of clinical appearance. A palatal cyst appears radiolucent on a radiographic examination and is not diagnosed through clinical appearance. A mixed tumor or pleomorphic adenoma is a benign tumor of salivary gland origin, found unilaterally off the midline of the hard palate. It is composed of tumor tissue that is not bony hard to palpation. *Ranula* is a term used for a mucocele-like lesion that forms unilaterally on the floor of the mouth.

REF: Torus Palatinus, page 21 OBJ: 4

WWW.NURSYLAB.COM