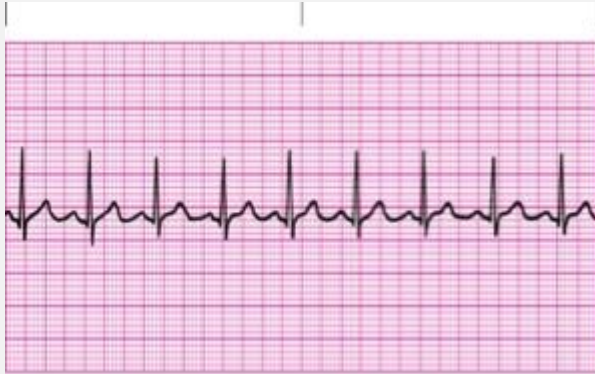


# RELIAS DYSRHYTHMIA BASIC A

## Normal sinus rhythm



Regular

Rate: 60-100

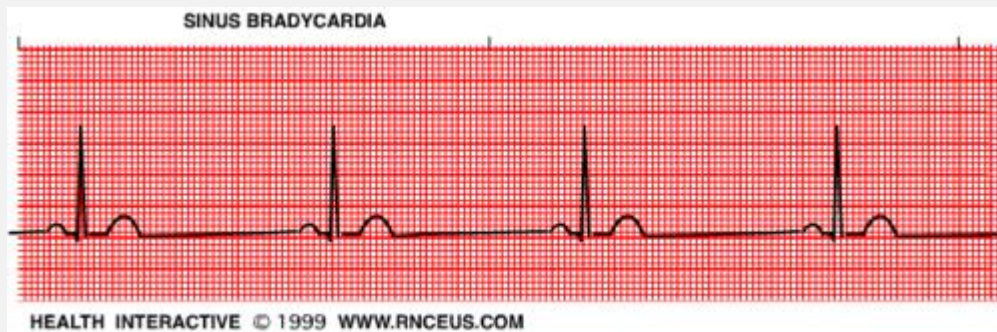
P Wave: Present, upright

PR Interval: 0.12-0.20 sec

QRS: <0.12 sec

learnexams

## Sinus Bradycardia



Regular

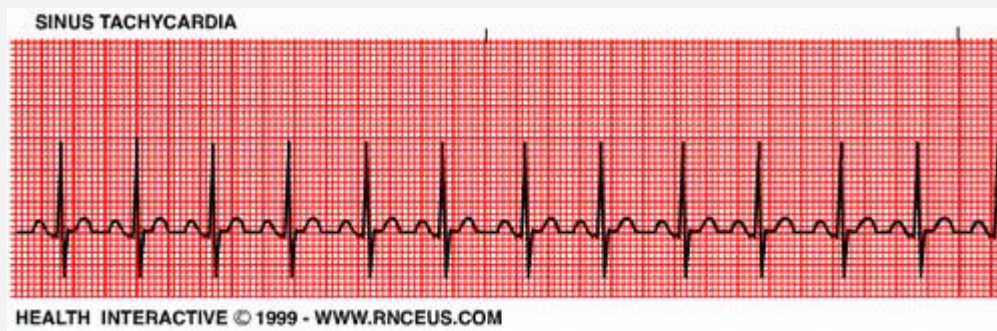
Rate: <60

P Wave: Present, upright

PR Interval: 0.12-0.20 sec

QRS: <0.12 sec

### Sinus Tachycardia



Regular

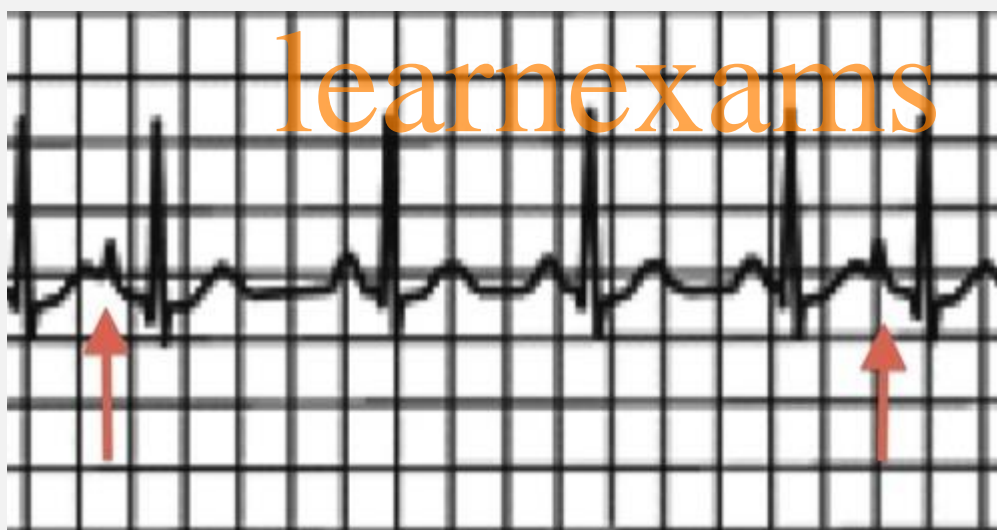
Rate: 100-150

P Wave: Present, upright

PR Interval: 0.12-0.20 sec

QRS: <0.12 sec

### Premature Atrial Contraction



IRREGULAR

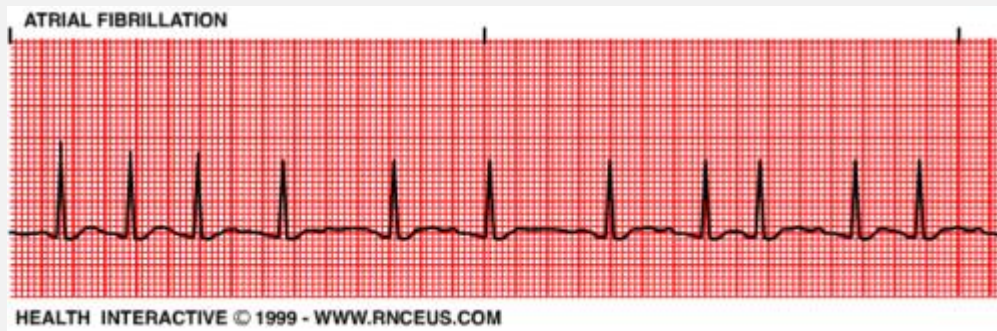
Rate: depends on underlying rhythm

P wave: Present or hidden in T wave

PR Interval: 0.12-0.20 sec

QRS: <0.12 sec

### Atrial Fibrillation



IRREGULAR

Atrial rate: UNMEASURABLE

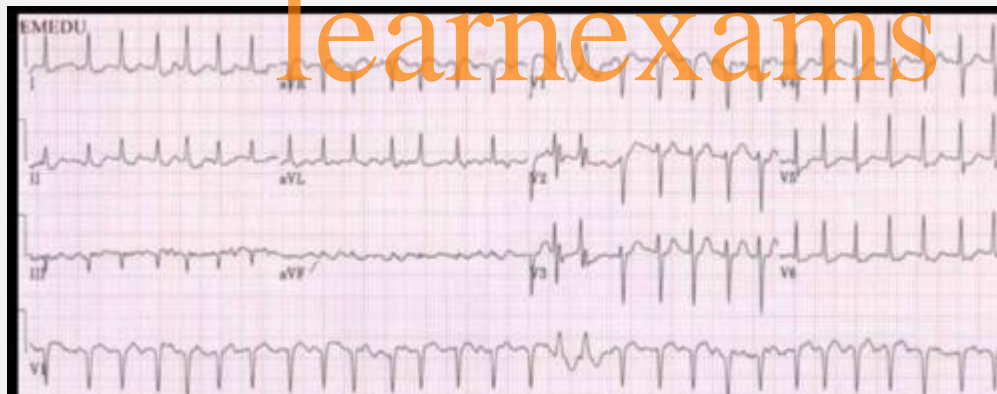Ventricular rate: variable

P wave: unable to see

PR Interval: N/A

QRS: <0.12 sec

### A fib RVR



IRREGULAR

Ventricular rate: 100-175

P wave: unable to see

PR Interval: N/A

QRS <0.12 sec